

## Original Article

# Ponte osteotomies increase risk of intraoperative neuromonitoring alerts in adolescent idiopathic scoliosis surgery

Elamir Bachar Harfouch<sup>1</sup>, Reem Fahd Bunyan<sup>2</sup>, Mona Al Faraidy<sup>3</sup>, Haitham H. Alnemari<sup>4,5</sup>, Shahid Bashir<sup>2</sup>

Departments of <sup>1</sup>Spine and <sup>2</sup>Neurology, Neuroscience Center, <sup>3</sup>Department of Anesthesia, King Fahad Specialist Hospital, Dammam, Saudi Arabia, <sup>4</sup>King Faisal Medical City, Abha, Saudi Arabia, <sup>5</sup>McMaster University, Hamilton, Canada.

E-mail: \*Elamir Bachar Harfouch - bacharharfouche@hotmail.com; Reem Fahd Bunyan - ReemF.Bunyan@kfsh.med.sa; Mona Al Faraidy - Mona.Faraidy@kfsh.med.sa; Haitham H. Alnemari - alhaitham78@live.com; \*Shahid Bashir - shahidbpk13@gmail.com



### \*Corresponding author:

Elamir Bachar Harfouch,  
Department of Spine,  
Neuroscience Center, King  
Fahad Specialist Hospital,  
Dammam, Saudi Arabia.

[bacharharfouche@hotmail.com](mailto:bacharharfouche@hotmail.com)

Received : 16 January 2022

Accepted : 07 March 2022

Published : 15 April 2022

### DOI

10.25259/SNI\_67\_2022

### Quick Response Code:



## ABSTRACT

**Background:** Ponte osteotomies (PO) are commonly used in adolescent idiopathic scoliosis (AIS) surgeries to improve the coronal and sagittal deformity correction. Here, we compared the incidence of perioperative neurologic complications for patients undergoing AIS with versus without PO.

**Methods:** In a retrospective cohort study of 80 consecutive AIS patients undergoing scoliosis correction, 40 underwent PO, while 40 did not. All operations were performed by one surgeon at one tertiary care center. Patients' demographics, Lenke classifications, surgical data, and deformity characteristics were comparable in both groups. Perioperative neurologic complications, defined as spinal cord or nerve root injuries identified by the surgeon, were tracked for those undergoing AIS surgery with or without PO being performed.

**Results:** The risk of IOM alerts was significantly higher in the PO patients (12.5%: 5 patients) versus those in the No-PO group (0%,  $P = 0.021$ ). Despite these changes, no patient incurred an increased postoperative deficit. Nevertheless, PO group patients demonstrated a higher coronal deformity correction rate (PO:  $71\% \pm 10.9$  vs. No-PO:  $64.2\% \pm 11.5$ ,  $P = 0.008$ ) and a greater kyphosis Cobb angle (PO:  $25.2 \pm 6$  vs. No-PO:  $17.5 \pm 9.4$ ,  $P = 0.0001$ ) on postoperative follow-up.

**Conclusion:** While PO improved 3D correction of AIS, it increased the risk of IOM alerts in 12.5% of cases.

**Keywords:** Adolescent idiopathic scoliosis, Ponte osteotomies, Spine deformity

## INTRODUCTION

The incidence of new neurological deficits for adolescent idiopathic scoliosis (AIS) surgery with intraoperative monitoring is low (i.e., overall rate of 0.73% and rate for deformity/kyphosis, reaching 3.43%).<sup>[3]</sup>

Ponte osteotomy (PO) is one of the most frequently used to achieve three-dimensional correction of a spinal deformity. PO or Grade 2 Schwab's osteotomy corrects long-segment thoracic kyphosis by shortening the posterior column in a single posterior stage.<sup>[1,2]</sup> It consists of wide resection of the thoracic facet joints and laminae and a complete removal of the ligamentum flavum.<sup>[1]</sup> However, performing PO likely increases, the risk for intraoperative IOM alerts and increased

postoperative deficits following surgical AIS correction.<sup>[5]</sup> Here, we compared the incidence of IONM alerts and new postoperative neurological deficits in 40 patients undergoing AIS surgery with versus 40 AIS performed without PO.

## MATERIALS AND METHODS

After obtaining approval from the Institutional Review Board, data for 80 consecutive operations performed by one spine surgeon for AIS at a tertiary care center were collected (2014–2018). Exclusion criteria were non-idiopathic cases, Lenke type 5 cases, and revision cases.

### Clinical analysis

Eighty cases were included in the study. The mean patient age was  $16.4 \pm 3.08$  years [Table 1]. Most patients were female (82.5%). The average thoracic Cobb angle was  $67.8 \pm 17.2^\circ$ . On bending film, the thoracic Cobb angle was  $47.4 \pm 16.8$ . The overall postoperative coronal correction rate was  $67.6 \pm 11.74$ . The thoracic kyphosis (T5–T12) was  $32.6 \pm 14.4$ . Curve distributions according to the Lenke classification were Type 1 (36.3%), Type 2 (30%), Type 3 (15%), Type 4 (11.3%), and Type 6 (7.1%). Patients' demographics and spinal deformity characteristics (i.e., including the coronal standing parameters and supine bending Cobb angles for the main thoracic [MT] curve and the thoracic kyphosis [T5–T12]) were studied before and after surgery. Cases were classified using the Lenke classification system. The correction index was calculated using the formula  $1 - \text{postoperative Cobb/preoperative Cobb}$ . Kyphosis change was calculated using the formula  $\text{postoperative kyphosis Cobb} - \text{preoperative kyphosis Cobb}$ .

Out of 80 patients, half had PO. There were no statically significant differences between the two groups in age, sex, Lenke type, preoperative thoracic Cobb, postoperative coronal thoracic Cobb, and thoracic coronal Cobb in the bending view [Table 2].

### Intraoperative neural monitoring (IOM)

An IOM alert was considered significant, if there was a decrease of more than 50% of the motor or somatosensory signal. IOM alerts related to anesthesia, systemic causes, and

technical neurophysiologic causes were not counted. Only cases that did not improve after the above-mentioned causes were counted.

### Summary of surgical technique

All procedures were performed on a Jackson table using IONM Bilateral pedicle screws that were placed at all levels using a free hand technique.<sup>[7]</sup> PO were performed (i.e., from Cobb to Cobb of the MT curve and 4–6 osteotomies are usually required per case). Deformity correction was obtained using 5.5 mm cobalt chromium rods; over-bent on the concave side and under-bent on the convex side. After the first concave rod insertion, distraction from the apex to the end was done and repeated 2–3 times to gain kyphosis. Then, the convex rod was inserted using the cantilevering technique.

### Statistical analysis

The two groups with and without PO were compared using the Student's *t*-test and Fisher's exact test, and results were confirmed by the nonparametric Mann–Whitney U-test. Data analysis was done using SPSS version 25.

**Table 2:** Comparison of all factors between OSTEO (PO vs. No-PO).

	OSTEO		P-value <sup>s</sup>
	PO (n=40)	No-PO (n=40)	
Preoperative Kyphosis D12-D5	29.0±13.1	36.2±14.9	0.026
Postoperative Kyphosis D12-D5	25.2±6.0	17.5±9.4	<0.001
Kyphosis change	-3.8±11.6	-18.6±10.1	<0.001
Sex	80% F, 20% M	85% F, 15% M	0.57
Age	16.7±3.4	16.1±2.6	0.338
Preoperative coronal MT Cobb	67.5±19.5	68.1±14.9	0.873
Bending MT Cobb	47.3±18.6	47.6±14.9	0.937
Postoperative Coronal MT Cobb	20.4±12.5	25.0±11.1	0.092
Coronal MT correction rate	71.0±10.9	64.2±11.5	0.008
IOM alert			
0	35 (46.7%)	40 (53.3%)	0.05 <sup>†</sup>
1	5 (100.0%)	0	
Type			
1	14 (48.3%)	15 (51.7%)	0.915 <sup>†</sup>
2	12 (50.0%)	12 (50.0%)	
3	7 (58.3%)	5 (41.7%)	
4	5 (55.6%)	4 (44.4%)	
6	2 (33.3%)	4 (66.7%)	

\*Results are expressed as mean±standard deviation, and number (%).

<sup>s</sup>: P-value has been calculated using Independent sample *t*-test and confirmed by nonparametric Mann–Whitney U-test. <sup>†</sup>P-value has been calculated using Fisher Exact test

Table 1: Demographic characteristics of 80 subjects.	
Age, mean (SD)	16.4±3.08
Sex	66 Female
Preoperative Kyphosis D12-D5 mean (SD)	32.6±14.4
Postoperative Kyphosis D12-D5 mean (SD)	21.4±8.7
Kyphosis change, mean (SD)	-11.2±13.1
Preoperative MT coronal Cobb angle, mean (SD)	67.8±17.2
Bending MT Cobb, mean (SD)	47.4±16.8
Postoperative MT Cobb, mean (SD)	22.7±12.05
Coronal MT correction rate, mean (SD)	67.6±11.7

## RESULTS

The correction rate was higher in the PO group:  $71\% \pm 10.9$  versus  $64.2\% \pm 11.5$  for the No-PO group [ $P = 0.008$ , Table 2].

The preoperative T5–T12 kyphosis was smaller in the PO group:  $29 \pm 13.1$  versus  $36.2 \pm 14.9$  for the No-PO group [ $P = 0.026$ , Table 2].

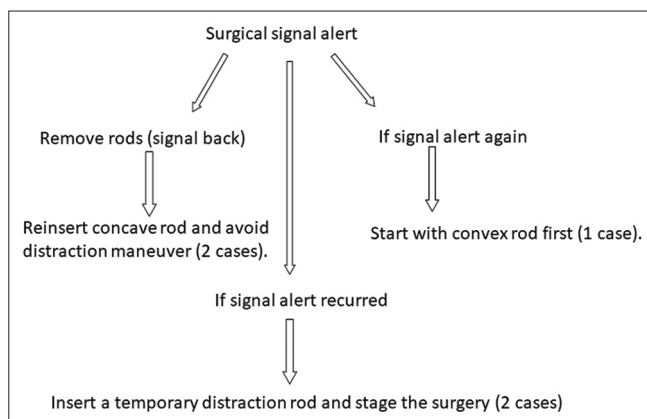
The postoperative kyphosis was higher in the PO group:  $25.2 \pm -6.0$  versus  $17.5 \pm 9.4$  for the No-PO group [ $P = 0.0001$ , Table 2].

The kyphosis change was less in the PO group:  $-3.8 \pm 11.6$  versus  $-18.6 \pm 10.1$  for the No-PO group [ $P = 0.0001$ , Table 2].

IOM alerts happened in five cases, all among the PO group [ $P = 0.02$ , Table 2].

### Advantages of PO accompanying AIS surgery

The 40 patients undergoing PO procedures with AIS surgery demonstrated a higher overall correction rate, a lesser degree of average change in postoperative kyphosis. However, five patients having PO during AIS surgery (12.5%) demonstrated significant intraoperative IOM changes versus none observed, where no PO were performed. Nevertheless, none of the five patients with such IOM changes during their AIS procedures ended up with new postoperative neurological deficits. [Figure 1] showed when a signal alert was considered surgical procedure. Signal alert improved in all patients after reversal of the last surgical maneuver, that is, removal of rod would reverse the signal. Concave rod reinsertion with distraction avoidance was enough to keep the signal (two cases). If this strategy fail, convex rod first insertion is helpful to spare the signal (one case). Otherwise, the case staged while using the temporary rod waiting for 1 week to optimize the patient. The surgery was finished using the same surgical plan without signal alert (two cases) [Figure 1].



**Figure 1:** Protocol for the management of surgical signal alert.

## DISCUSSION

### Complication rates for PO used in AIS surgery

Although PO help in the 3D correction of the AIS deformity,<sup>[4]</sup> serious complications may happen due to an increase in corrective forces.<sup>[8]</sup> Shah reported IOM alerts of 8% in a study of 87 patients with a thoracic Cobb angle of  $57 \pm 9.7$  in Lenke types 1–4.<sup>[7]</sup> In the present study, 80 cases showed that the average thoracic Cobb angle was  $67.8 \pm 17.2^\circ$  with the Lenke classification, which were Type 1, 2, 3, 4, and 6. There were no statically significant differences between the two groups in age, sex, Lenke type, preoperative thoracic Cobb, postoperative coronal thoracic Cobb, and thoracic coronal Cobb in the bending view [Table 2]. In a multicenter study of 2210 surgical AIS patients, the incidence of IOM alerts was 9.3% in patients who underwent PO and 4.2% in patients without PO.<sup>[3]</sup> Our comparative study notes a major difference in IOM alerts between the two groups (PO: 12.5% vs. No-PO: 0%,  $P = 0.021$ ). Our overall coronal Cobb deformity was  $67.8 \pm 17.2^\circ$ ; this difference in Cobb angle may explain the higher rate of IOM alerts in our PO group.

### Higher correction rate in PO patients undergoing AIS surgery

In a multicenter study of 191 subjects comparing PO and No-PO subjects, Samadani *et al.* 2015 showed a higher correction rate in the PO group ( $67.1\%$  vs.  $61.8\%$ ,  $P = 0.01$ ).<sup>[6]</sup> Our patients' correction rate was  $71\% \pm 10.9$  for the PO group and  $64.2\% \pm 11.5$  for the No-PO group ( $P = 0.008$ ). This better correction rate in our patients may be related to our all-levels screw fixation system.

### Better kyphosis outcomes with PO in AIS surgery

The kyphosis outcome was significantly better in the PO group ( $25.2 \pm 6$  vs. No-PO:  $17.5 \pm 9.4$ ,  $P = 0.0001$ ). We had a kyphosis decrease in both groups, which was more obvious in the PO group, where the kyphosis change was higher ( $-3.8 \pm 11.6$  vs. No-PO:  $-18.6 \pm 10.1$ ,  $P = 0.0001$ ). This study showed the importance of good intraoperative neurophysiology monitoring during spinal deformity surgeries, especially when three-dimensional correction of the deformity is the goal.

## CONCLUSION

In 40 patients, PO improved AIS correction in all planes, but increased the risk of IOM alerts in 5 (12.5%) of cases. Utilizing resuscitative techniques to address these alerts/significant changes, we avoided postoperative neurological deficits in all five cases.

### Declaration of the patient consent

Institutional Review Board (IRB) permission obtained for the study.

### Financial support and sponsorship

Nil.

### Conflicts of interest

There are no conflicts of interest.

### REFERENCES

1. Dickson RA, Lawton JO, Archer IA, Butt WP. The pathogenesis of idiopathic scoliosis. Biplanar spinal asymmetry. *J Bone Joint Surg Br* 1984;66:8-15.
2. Feng B, Qiu G, Shen J, Zhang J, Tian Y, Li S, *et al.* Impact of multimodal intraoperative monitoring during surgery for spine deformity and potential risk factors for neurological monitoring changes. *J Spinal Disord Tech* 2012;25:E108-14.
3. Hamilton DK, Smith JS, Sansur CA, Glassman SD, Ames CP, Berven SH, *et al.* Rates of new neurological deficit associated with spine surgery based on 108,419 procedures: A report of the scoliosis research society morbidity and mortality committee. *Spine (Phila Pa 1976)* 2011;36:1218-28.
4. Imrie M, Yaszay B, Bastrom TP, Wenger DR, Newton PO. Adolescent idiopathic scoliosis: Should 100% correction be the goal? *J Pediatr Orthop* 2011;31:S9-13.
5. Nash CL Jr., Lorig RA, Schatzinger LA, Brown RH. Spinal cord monitoring during operative treatment of the spine. *Clin Orthop Relat Res* 1977;126:100-5.
6. Samdani AF, Bennett JT, Singla AR, Marks MC, Pahys JM, Lonner BS, *et al.* Do Ponte Osteotomies enhance correction in adolescent idiopathic scoliosis? An analysis of 191 Lenke 1A and 1B curves. *Spine Deform* 2015;3:483-8.
7. Shah SA, Dhawale AA, Oda JE, Yorgova P, Neiss GI, Holmes L Jr., *et al.* Ponte osteotomies with pedicle screw instrumentation in the treatment of adolescent idiopathic scoliosis. *Spine Deform* 2013;1:196-204.
8. Vauzelle C, Stagnara P, Jouvinroux P. Functional monitoring of spinal cord activity during spinal surgery. *Clin Orthop Relat Res* 1973;93:173-8.

**How to cite this article:** Harfouch EB, Bunyan RF, Faraidy MA, Alnemari HH, Bashird S. Ponte osteotomies increase risk of intraoperative neuromonitoring alerts in adolescent idiopathic scoliosis surgery. *Surg Neurol Int* 2022;13:154.